

## CHRONIC TRAUMATIC ENCEPHALOPATHY IN A NATIONAL FOOTBALL LEAGUE PLAYER: PART II

### Bennet I. Omalu, M.D., M.P.H.

Departments of Pathology and Epidemiology, University of Pittsburgh, Pittsburgh, Pennsylvania

### Steven T. DeKosky, M.D.

Departments of Human Genetics and Neurology, University of Pittsburgh, Pittsburgh, Pennsylvania

### Ronald L. Hamilton, M.D.

Department of Pathology, University of Pittsburgh, Pittsburgh, Pennsylvania

### Ryan L. Minster, M.S.I.S.

Department of Human Genetics, University of Pittsburgh, Pittsburgh, Pennsylvania

### M. Ilyas Kamboh, Ph.D.

Department of Human Genetics, University of Pittsburgh, Pittsburgh, Pennsylvania

### Abdulrezak M. Shakir, M.D.

Department of Pathology, University of Pittsburgh, Pittsburgh, Pennsylvania

### Cyril H. Wecht, M.D., J.D.

Departments of Pathology and Epidemiology, University of Pittsburgh, Pittsburgh, Pennsylvania

#### Reprint requests:

Bennet I. Omalu, M.D., M.P.H., 7520 Penn Bridge Court, Pittsburgh, PA 15221. Email: bennet.omalu@verizon.net

Received, January 4, 2006.

Accepted, June 30, 2006.

**OBJECTIVE:** We present the second reported case of autopsy-confirmed chronic traumatic encephalopathy in a retired professional football player, with neuropathological features that differ from those of the first reported case. These differing pathological features underscore the need for further empirical elucidation of the pathoe-tiology and pathological cascades of long-term neurodegenerative sequelae of professional football.

**METHODS:** A psychological autopsy was performed with the next-of-kin and wife. Medical and hospital records were reviewed. A complete autopsy was accompanied by a comprehensive forensic neuropathological examination. Restriction fragment length polymorphism analysis was performed to determine apolipoprotein-E genotype.

**RESULTS:** Pertinent premortem history included a 14-year span of play in organized football starting from the age of 18 years. The subject was diagnosed with severe major depressive disorder without psychotic features after retirement, attempted suicide multiple times and finally committed suicide 12 years after retirement by ingestion of ethylene glycol. Autopsy revealed cardiomegaly, mild to moderate coronary artery disease, and evidence of acute ethylene glycol overdose. The brain showed no atrophy, a cavum septi pellucidi was present, and the substantia nigra showed mild pallor. The hippocampus and cerebellum were not atrophic. Amyloid plaques, cerebral amyloid angiopathy, and Lewy bodies were completely absent. Sparse to frequent  $\tau$ -positive neurofibrillary tangles and neuropil threads were present in all regions of the brain. Tufted and thorn astrocytes, as well as astrocytic plaques, were absent. The apolipoprotein-E genotype was E3/E4.

**CONCLUSION:** Our first and second cases both had long careers without multiple recorded concussions. Both manifested Major Depressive Disorder after retirement. Amyloid plaques were present in the first case and completely absent in the second case. Both cases exhibited neurofibrillary tangles, neuropil threads, and coronary atherosclerotic disease. Apolipoprotein-E4 genotypes were different. Reasons for the contrasting features in these two cases are not clear. Further studies are needed to identify and define the neuropathological cascades of chronic traumatic encephalopathy in football players, which may form the basis for prophylaxis and therapeutics.

**KEY WORDS:** Chronic traumatic encephalopathy, National Football League, Professional football players

*Neurosurgery* 59:1086-1093, 2006

DOI: 10.1227/01.NEU.0000245601.69451.27

www.neurosurgery-online.com

In 2005, we reported the first autopsy-confirmed case of chronic traumatic encephalopathy (CTE) in a National Football League (NFL) player (5, 27). The brain in that report showed diffuse amyloid plaques, neuropil threads (NT) and neurofibrillary tangles (NFT) in the neocortex. There were no diffuse amyloid plaques, NTs, or NFTs in the entorhi-

nal cortex or hippocampus. We now report the second autopsy-confirmed case of CTE in another NFL player with neuropathological findings that are somewhat distinct from the initial reported case. In contrast to the first case, the brain in this second case revealed topographically distributed sparse to frequent NFT and NT in the neocortex, hippocampus,

subcortical ganglia, and brainstem. There were no diffuse amyloid plaques. Whereas the apolipoprotein-E (APOE) genotype of our first case was E3/E3, the APOE genotype of this second case was E3/E4.

Chronic neurodegenerative changes have been causally associated with contact sports, including boxing, soccer, and American football (7, 13–15, 39, 40, 43, 45, 53). Autopsies aimed at diagnosing CTE are virtually non-existent in active or retired NFL players. This has precluded definitive elucidation of pathological cascades of chronic neurodegenerative sequelae of professional football by direct tissue analyses. Since the 1995 recommendation of the NFL Committee on Mild Traumatic Brain Injury (MTBI) for the NFL to fund research into MTBI, significant progress has been made in understanding and ameliorating or preventing acute MTBI (28–37, 50–52). However, we currently know little regarding the chronic neurodegenerative outcomes of long-term play in professional football. The differing pathological findings in our two cases, especially the absence of amyloid plaques in the second case, underscore the urgent need for further information and possibly a prospective, longitudinal study of former professional football players. Such a study, combining neurological, neuropsychiatric, neuroimaging, and post-mortem neuropathological facets and findings, might form the basis for possible prophylaxis and therapeutics.

### Premortem History

A psychological autopsy of this 45-year-old African-American man was performed with his next-of-kin and wife. He had married twice and had no children. At the time of his death, he lived alone and was separated from his second wife. He enlisted in the United States Armed Forces in 1977 after high school and served for 2 years. He began playing football at the age of 18 years, while in the military, and played as an offensive tackle for 2 years. He entered college after military service and moved on to a college football scholarship, during which time he played as a starting offensive line tackle for 4 years (1980–1984). In 1984, he was drafted by the NFL as a right guard and played for 8 consecutive years (1984–1992). He sustained several musculoskeletal and cartilage injuries while playing professional football, which necessitated multiple knee, elbow, and shoulder surgeries. He had indicated to his second wife that he sustained repeated mild concussions of his head on numerous occasions during his football career.

During his childhood and during his amateur and professional football career, his wife and family did not observe any obvious psychosocial or behavioral abnormality. However, within several years of his retirement from the NFL, his wife reported that he became increasingly quiet and that he was afraid and fearful, with paranoid tendencies. On some occasions, he would sweat profusely in public settings and become agitated when approached by other people. At other times, he was noted to exhibit a reassured, confident, and approachable demeanor. In private, he sometimes became extremely reclusive and distanced himself from all personal interactions with family and friends, often locking himself in the house for 1 to

2 days. He would later seek companionship from family and friends as if nothing had happened. He manifested unpredictable fluctuations in mood and personality.

Before his retirement, the decedent had started a sole proprietorship business in 1988. He began working as a sales manager for another business entity in 1992. In 1993, he formed a second wholesale produce corporation. In 1994, he diversified his business and expanded into food processing and manufacturing and created yet another new corporation. His business activities and decisions were regarded as extraordinarily risky, ambitious, and rather irrational. In business dealings, he also exhibited sudden and unexpected fluctuations in mood and personality. At some times, he appeared hard working, ambitious, and highly driven, but at others, he exhibited sudden bouts of agitation and irritability with no clear instigator. He would lose his ability to focus and concentrate and would become highly emotional, which led to failure of his business operations. In 2000, he further expanded his food service business and formed another sole proprietorship entity.

He was described by the next-of-kin as having “extreme highs and lows.” He became progressively incapable of mentally handling very complex rational thoughts in matters of daily living and business. He became increasingly impulsive and paranoid. His erratic behavior continued to worsen; he exhibited disinhibition, began having financial problems, and could not sustain his businesses.

He began outpatient psychotherapy in 1992 after his first suicide attempt in 1991 by ingestion of rat poison and cold medications, after suspension from the NFL for violating the NFL’s steroid policy. He was diagnosed with adjustment disorder with depressed mood after this first suicide attempt. He made several subsequent suicide attempts by ingestion of prescription drugs and antifreeze. He verbalized thoughts of suicide and attempted suicide again in 2003, shortly after he was investigated for a fire that destroyed his business. In 2005, he was indicted for arson and wrongful business transactions for apparently setting fire to his factory plant. His behavior became increasingly characterized by constant thoughts of suicide, and he was admitted for psychiatric treatment three times. A few weeks after his last discharge from the hospital, he was found lying on a couch with altered mental status; he died at a local hospital several hours later. Laboratory analyses of his blood and urine samples performed before his death revealed metabolic acidosis with increased blood lactic acid, negative base excess, high anion gap, high serum osmolality, hypocalcemia, and positive urine oxalate crystals.

There was no contributory family history relative to significant medical problems or severe depression/suicide attempts. There was a documented single episode of a rollover of a sport utility vehicle which he was driving when he swerved to avoid hitting a deer. He experienced a brief loss of consciousness at the scene, but recovered completely. There was at least one clinically documented severe concussive brain injury during play of football in 1987, which necessitated removal from play for at least 1 week. He was hospitalized for one night and complained of lightheadedness, unsteadiness in gait, and difficulty

concentrating. These symptoms were present for at least several days. Medical records from a local psychiatric hospital, where the decedent received follow-up psychiatric treatment, revealed a primary psychiatric diagnosis of major depressive disorder, which was severe and without psychotic features. Other significant medical history included thyroidectomy (2 mo before death) for hyperthyroidism (Grave's disease).

### Relevant Findings on General Autopsy

A complete autopsy was performed at the Allegheny County Coroner's Office. External examination revealed a well-developed, well-nourished African-American man who weighed 275 pounds and measured 72 inches and seemed consistent with the stated age of 45 years. There was no evidence of recent blunt force, penetrating force, or projectile trauma. Internal examination revealed a heart weight of 580 g. The heart showed patchy myofibrillary hypertrophy with focal infiltration of the subendocardium by neutrophils. The coronary arteries showed mild to moderate eccentric, segmental atherosclerosis with 40 to 60% multifocal luminal occlusion. The lungs showed moderate acute pulmonary edema and congestion. The right and left kidneys appeared grossly unremarkable; however, numerous intratubular oxalate crystals were found in histology sections of the kidneys. Postmortem toxicological analyses of blood and urine revealed the presence of ethylene glycol in the urine, with a level of 460 mg/dl. There was no ethylene glycol detected in the blood (ethylene glycol has a short half-life, of 2.5–4.5 h).

### Neuropathological Findings

The dura mater revealed no hemorrhages, xanthochromia, or subdural membranes. The brain weighed 1535 g in the fresh state. The cerebral and cerebellar hemispheres appeared symmetrical and revealed no anomalous gyral-sulcal convolutions, atrophy, contusions, infarcts, or hemorrhages. There was global edema and congestive swelling. The leptomeninges appeared normal, as did the vessels of the circle of Willis and the basilar and vertebral arteries. The cranial nerves were normal.

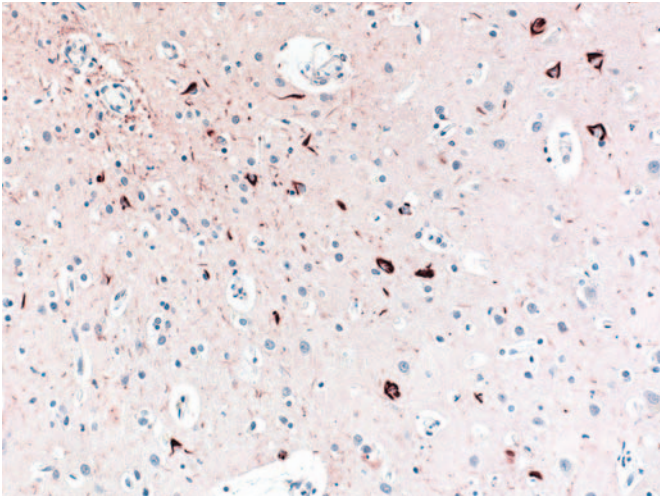
The neocortical gray ribbon was intact and the gray-white matter demarcation distinct. The centrum semiovale and the periventricular white matter revealed diffuse edema and congestion without hemorrhages, infarcts, or demyelination. The ventricles contained no abnormal fluid, were symmetrically compressed, and showed normal ependymal lining. A cavum septi pellucidi was present, compressed, and measured 0.9 × 0.1 cm at the coronal level of the nucleus accumbens. The septum pellucidum showed no fenestrations. The choroid plexuses were congested. The lamina terminalis and superior and inferior medullary vela were intact. The corpus callosum was not atrophic and was without hemorrhage or demyelination. The caudate nucleus, putamen, globus pallidus, thalamus, and subthalamic nucleus were normal, without lacunar infarcts or hemorrhages. The substantia nigra showed mild pallor. The internal capsule, basal nucleus of Meynert, amygdala, and piriform cortex were intact and without atrophy. The hippocam-

pus and parahippocampal gyrus revealed no anomalies or gross atrophy. The mamillary bodies and hypothalamus were normal. The midbrain, pons, and medulla oblongata revealed no hemorrhages, infarcts, or demyelination. The pituitary gland was normal.

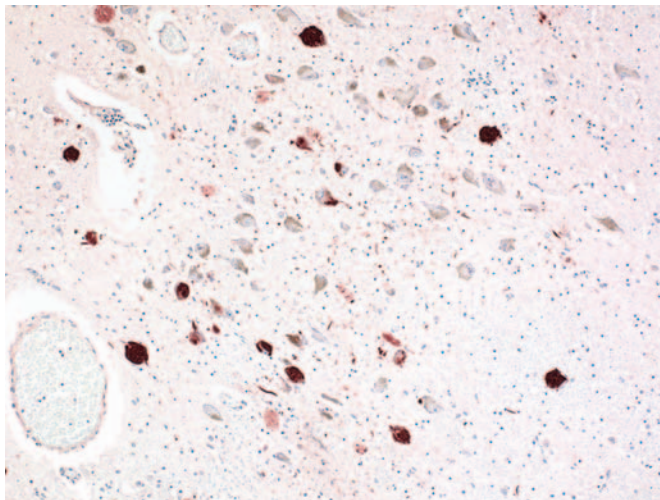
Sections from 23 brain areas were submitted for histological tissue processing and analysis, including the middle frontal gyrus, cingulate gyrus, anterior corpus callosum, caudate nucleus, insula cortex, putamen and globus pallidus, hippocampus at the level of the lateral geniculate body, thalamus, midbrain at the level of the red nucleus and the substantia nigra, pons at the level of the locus ceruleus, medulla at the level of the inferior olivary nucleus, cerebellum with dentate nucleus, basal nucleus of Meynert, amygdala, inferior parietal lobule, superior and middle temporal gyri, occipital lobecalcary cortex, superior cerebellar vermis, splenium of corpus callosum, mamillary body and hypothalamus, pituitary gland, and dura mater. The following histochemical and immunohistochemical stains were performed on each section of the brain: hematoxylin and eosin,  $\beta$ -A4 amyloid immunostain,  $\tau$  protein immunostain, neurofilament immunostain,  $\alpha$ -synuclein immunostain, ubiquitin immunostain, amyloid precursor protein immunostain, and Bielschowsky silver impregnation stain. The section of the dura mater was stained only with hematoxylin and eosin.

Microscopic examination revealed sparse to moderate infiltration of the leptomeninges by neutrophils, accompanied by acute congestion of the leptomeningeal vessels, consistent with ethylene glycol-induced chemical leptomeningitis (16). There was mild neocortical neuronal dropout in the frontal, parietal, and temporal lobes, with residual normal laminar and columnar organization. Swollen, achromasic, or ballooned neurons were absent. There was mild extracellular edema of the cortical gray and white matter. Very focal and sparse perivascular oxalate microcrystals were noted. The centrum semiovale and the corpus callosum revealed no demyelination, pallor, or axonal spheroids. The ependymal lining showed intermittent denudations with focal infiltration of the occipital horn by neutrophils. There was patchy subependymal gliosis. The globus pallidus showed mild neuronal dropout. The internal, external, and extreme capsules and claustrum revealed no demyelination or degeneration.

The Sommer's sector, presubiculum and subiculum revealed cytoplasmic eosinophilia of many pyramidal neurons without neuronal dropout. The basal nucleus of Meynert and the amygdala revealed no neuronal dropout. The substantia nigra revealed mild neuronal dropout accompanied by mild extraneuronal pigment. The locus ceruleus also revealed mild neuronal dropout. The medulla oblongata revealed mild neuronal dropout and astrogliosis of the dorsal inferior olivary nucleus. There was mild neuronal dropout of the Purkinje neurons, without acute eosinophilic degeneration, as well as mild Bergmann astrogliosis. There was mild neuronal dropout of the internal granule cell layer and the dentate nucleus, which revealed mild fibrillary astrogliosis. The adenohypophysis revealed focal interstitial fibrosis with very focal sparse infiltration by



**FIGURE 1.** Photomicrograph (×100) of a section of the frontal neocortex immunostained for  $\tau$  protein, showing frequent NFTs and NTs.



**FIGURE 2.** Photomicrograph (×100) of a section of the locus ceruleus immunostained for  $\tau$  protein, showing frequent NFTs and NTs.

lymphocytes. The neurohypophysis was unremarkable. The dura mater was congested and revealed no inflammation or remote hemorrhage.

**Immunohistochemical Findings**

Diffuse or neuritic amyloid plaques and cerebral amyloid angiopathy were absent in all regions of the brain examined.  $\tau$ -positive band- and flame-shaped small and large globose perikaryal NFT were topographically observed in several regions (Figs. 1 and 2). The NFTs were also accompanied by  $\tau$ -positive NTs. Large globose NFTs were found only in the midbrain, pons, basal nucleus of Meynert, substantia nigra, mammillary bodies, and hypothalamus. Table 1 shows the dis-

**TABLE 1.** Summary of topographic distribution and density of neurofibrillary tangles and neuropil threads<sup>a</sup>

Region of the brain	Density of NFTs	Density of NTs
Frontal lobe, left	+++	++
Cingulate gyrus, corpus callosum, and caudate nucleus, left		
<i>Cingulate cortex</i>	+	+
<i>Caudate nucleus</i>	+*	+*
Insular cortex, putamen and globus pallidus, left		
<i>Insular cortex</i>	++*	++*
<i>Putamen</i>	+*	+*
<i>Globus pallidus</i>	0	0
Hippocampus, left		
CA-1, CA-2, CA-3	+	+
<i>Subiculum, presubiculum</i>	+	+
<i>Entorhinal cortex</i>	+++	+++
Thalamus, left	+	+
Midbrain, level of red nucleus		
<i>Superior colliculi/oculomotor nucleus</i>	+	+
<i>Substantia nigra</i>	++*	++*
Pons, level of locus ceruleus		
<i>Locus ceruleus</i>	+++	+++
<i>Other pontine tegmental nuclei</i>	+	+
Medulla	+	+
Cerebellum	0	0
Basal nucleus of Meynert	+	+
Amygdala	++	+
Inferior parietal lobule, left	++	+
Superior and middle temporal gyri, left	+++	++
Occipital lobe, calcarine cortex, left	0	0
Superior cerebellar vermis	0	0
Splenium of corpus callosum		
<i>Posterior cingulate cortex</i>	+	+*
<i>Corpus callosum</i>	n/a	0
Hippocampus, right		
<i>Cornu ammonis (CA1–3)</i>	++	++
<i>Subiculum</i>	+	+
<i>Entorhinal cortex</i>	++	++
Mamillary body and hypothalamus, left	++	++
Substantia nigra, cut left side	++	++
Rostral pons/caudal midbrain		
<i>Locus ceruleus</i>	+++	+++
<i>Other tegmental nuclei</i>	+	+
Mid/caudal pons		
<i>Locus ceruleus</i>	+++	+++
<i>Other tegmental nuclei</i>	+	+

<sup>a</sup> NFTs, neurofibrillary tangles; NTs, neuropil threads; +, sparse density; ++, moderate density; +++, frequent density; +\*+, sparse-to-moderate density; +\*, very sparse; n/a, not applicable.

tribution and density of NFTs and NTs in the regions of the brain examined. The determination of the density of NFTs and NTs was adapted from the density distribution of neuritic plaques by the Consortium to Establish a Registry for Alzheimer's Disease, which is used for the neuropathological diagnosis of Alzheimer's disease (9, 12, 23). One or two astrocytes in the subcortical white matter showed focal cytoplasmic fibrillary  $\tau$  immunoreactivity.  $\tau$ -positive tufted astrocytes, thorn astrocytes, and astrocytic plaques were absent in all regions of the brain examined. Lewy bodies, Lewy-related neurites,  $\alpha$ -synuclein-positive glial inclusions, and neuronal or glial ubiquitin-positive inclusions were absent in all regions of the brain examined.

Acute toxic axonal injury and cerebral edema caused by acute ethylene glycol intoxication was evinced by multifocal axonal white matter immunoreactivity for amyloid precursor protein in the subcortical white matter and brainstem (15, 25).

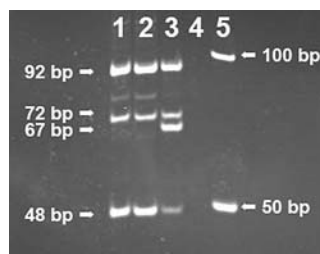### APOE Genotyping

Genomic deoxyribonucleic acid (DNA) was extracted from whole blood using the QIAamp DNA Blood Mini Kit (Qiagen, Valencia, CA). Restriction fragment length polymorphism analysis with Hha I (New England Biolabs, Beverly, MA) was completed using previously published protocols (20, 27). The genotype of the sample was determined to be E3/E4 (Fig. 3).

## DISCUSSION

Major depression, dementia-related syndromes, and neuropsychological and sensory motor deficits have been reported in professional and amateur contact sport players, including NFL players (6, 8, 10, 17–19, 21, 22, 38, 46–49). The neuropathological findings responsible for these neuropsychiatric deficits have not been clearly defined because of the rarity of autopsies in retired NFL players.

Our case represents a retired professional player (who played a total of 14 yr of organized football) who had developed a progressive major depressive disorder after retirement from football, accompanied by repeated suicide attempts and a completed suicide by ingestion of ethylene glycol. Autopsy confirmed the presence of abnormal metabolism and widespread neuronal and neuropil accumulation of a cytoskeletal protein to form NFTs and



**FIGURE 3.** Polyacrylamide gel electrophoresis showing DNA stained with ethidium bromide visualized with ultraviolet light. Lanes 1 and 2 contain duplicate samples of the DNA extracted from the brain sample amplified as described in the text and digested with Hha to reveal the restriction fragment length polymorphism. Lane 3 is a sample known to be E2/E4 prepared in parallel with the samples from Lanes 1 and 2. Lane 4 is a negative template control. Lane 5 contains a 50 to 2000 basepair ladder.

NTs. The major components of NFTs and NTs are hyperphosphorylated paired helical filaments of the microtubule-binding protein,  $\tau$  (16).

Abnormal metabolism and accumulation of neuronal cytoskeleton and membrane proteins have been suggested to be pathoetiological components of delayed neurological sequelae of single or repeated MTBI sustained in contact sports (2, 13, 14, 41, 42). The morphophenotype of our case, i.e., the presence of NFTs without amyloid plaques, supports previous findings of Geddes et al. (13, 14) who found only NFTs in the brains of five young adults who had experienced

mild chronic head injuries. Geddes et al. (13, 14) had hypothesized that repetitive head injury in young adults may be initially associated with neocortical NFT formation in the absence of  $\beta$ -amyloid.

The APOE genotypes of our two reported cases were different (E3/E3 and E3/E4). We currently do not have any explanation for this difference. However, it confirms what is already known regarding APOE genotype (3, 11, 24, 25, 44). Individuals who inherit one or two copies of APOE4 may exhibit a three-to-

**TABLE 2. Common and contrasting features of two reported cases of chronic traumatic encephalopathy in two retired National Football League players<sup>a</sup>**

Characteristics	Patient 1	Patient 2
Age at death	50 years	45 years
Approximate age when decedent was drafted into the NFL	22 years	25 years
Duration of professional play in the NFL	17 years	8 years
Approximate duration of play of football in high school, college, and/or in the military	5 years	6 years
Interval between retirement from the NFL and death	12 years	12 years
History and diagnosis of major depressive disorder after retirement from the NFL	Present	Present
Gross atrophy of the brain and hydrocephalus ex vacuo	Absent	Absent
Fenestrations of the septum pellucidum	Absent	Absent
Cavum septi pellucidi	Absent	Present
Presence of diffuse amyloid plaques	Present	Absent
Presence of NFTs and NTs	Present	Present
APOE genotype	E3/E3	E3/E4
Postmortem diagnosis of coronary atherosclerotic disease	Present	Present
Premortem history of steroid use	Present	Present

<sup>a</sup> NFL, National Football League; NFTs, neurofibrillary tangles; NTs, neuropil threads; APOE, apolipoprotein-E.

ninefold increase in developing chronic posttraumatic neurodegeneration. However, the presence of the APOE4 allele does not confer absolute predisposition to CTE, and absence of APOE4 does not confer absolute protection from CTE.

Table 2 illustrates the common and contrasting features of our two reported cases of CTE in two NFL players. Both had long careers without multiple recorded concussions. Reasons for contrasting features in the two cases are not clear. There was a history of steroid use during play in the NFL in both cases. This observation may suggest that there is an unconfirmed possibility that steroid use may play a role in the pathoetiology of CTE. However, we cannot allude to this role of steroid use at this time. Further studies are needed to identify and define the pathoetiological factors and neuropathological cascades of CTE in retired football players.

The neuropsychiatric presentation and clinical course of CTE in football players and other contact-sport players including boxers (dementia pugilistica) may exhibit a spectrum of neuropsychiatric and neuropathological cascades. However, definitive characteristics of CTE in contact sports and American football should be determined by long-term, longitudinal, multi-institutional, and multidisciplinary studies, which will comprise genetic analysis and scheduled intermittent neuropsychiatric testing and follow-up, accompanied by neuroradiological monitoring of a specified cohort of professional contact-sport players, such as the players in the NFL Hall of Fame. Autopsies and comprehensive postmortem neuropathological examinations should be performed on all participants in these studies for brain tissue analysis and clinicopathological correlations.

REFERENCES

1. Abreau F, Templar DI, Schuyler BA, Bradley A, Hutchison HT: Neuropsychological assessment of soccer players. *Neuropsychology* 4:175-181, 1990.
2. Allsop D, Haga S, Bruton C, Ishii T, Roberts GW: Neurofibrillary tangles in some cases of dementia pugilistica share antigens with amyloid beta-protein of Alzheimer's disease. *Am J Pathol* 136:255-260, 1990.
3. Bales KR, Dodart JC, DeMattos RB, Holtzman DM, Paul SM: Apolipoprotein E, amyloid, and Alzheimer disease. *Mol Interv* 2:363-375, 339, 2002.
4. Barth JT, Macciocchi SN, Giordani B, Rimel R, Jane JA, Boll TJ: Neuropsychological sequelae of minor head injury. *Neurosurgery* 13:529-533, 1983.
5. Casson IR, Pellman EJ, VianoDC: Chronic traumatic encephalopathy in a National Football League Player. *Neurosurgery* 58:E1003, 2006 (comment).
6. Collins MW, Grindel SH, Lovell MR, Dede DE, Moser DJ, Phalin BR, Nogle S, Wasik M, Cordry D, Daugherty KM, Sears SF, Nicolette G, Indelicato P, McKeag DB: Relationship between concussion and neuropsychological performance in college football players. *JAMA* 282:964-970, 1999.
7. Corsellis JA, Bruton CJ, Freeman-Browne D: The aftermath of boxing. *Psychol Med* 3:270-303, 1973.
8. Drew RH, Templar DI, Schuyler BA, Newell TG, Cannon WG: Neuropsychological deficits in active licensed professional boxers. *J Clin Psychol* 42:520-525, 1986.
9. Ellison D, Love S, Chimelli L, Harding BM, Rowe J, Vinters HV: *Neuropathology: A Reference Text of CNS Pathology*. Edinburgh and New York, Mosby, 2004, ed 2.
10. Erlanger DM, Kutner KC, Barth JT, Barnes R: Neuropsychology of sports-related head injury: Dementia pugilistica to post concussion syndrome. *Clin Neuropsychol* 13:193-209, 1999.

11. Friedman G, Froom P, Sazbon L, Grinblatt I, Shochina M, Tsender J, Babaey S, Yehuda B, Groswasser Z: Apolipoprotein E-epsilon4 genotype predicts a poor outcome in survivors of traumatic brain injury. *Neurology* 52:244-248, 1999.
12. Gearing M, Mirra SS, Hedreen JC, Sumi SM, Hansen LA, Heyman A: The Consortium to Establish a Registry for Alzheimer's Disease (CERAD). Part X. Neuropathology confirmation of the clinical diagnosis of Alzheimer's disease. *Neurology* 45:461-466, 1995.
13. Geddes JF, Vowles GH, Nicoll JA, Revesz T: Neuronal cytoskeletal changes are an early consequence of repetitive head injury. *Acta Neuropathol (Berl)* 98:171-178, 1999.
14. Geddes JF, Vowles GH, Robinson SF, Sutcliffe JC: Neurofibrillary tangles, but not Alzheimer-type pathology, in a young boxer. *Neuropathol Appl Neurobiol* 22:12-16, 1996.
15. Gentleman SM, Graham DI, Roberts GW: Molecular pathology of trauma: Altered  $\beta$ APP metabolism and the aetiology of Alzheimer's Disease, in Kogure K, Hossmann KA, Siesjö BK (eds): *Neurobiology of Ischemic Brain Damage (Progress in Brain Research)*. Amsterdam, Elsevier, 1993, pp 237-246.
16. Greenfield JG, Graham DI, Lantos PL: *Greenfield's Neuropathology*. London, Arnold, 2002 vol 1, pp 823-898; vol 2, pp 195-272.
17. Guskiewicz KM, Marshall SW, Bailes J, McCrea M, Cantu RC, Randolph C, Jordan BD: Association between recurrent concussion and late-life cognitive impairment in retired professional football players. *Neurosurgery* 57:719-726, 2005.
18. Jorge R, Robinson RG: Mood disorders following traumatic brain injury. *Int Rev Psychiatry* 15:317-327, 2003.
19. Jorge RE, Robinson RG, Moser D, Tateno A, Crespo-Facorro B, Arndt S: Major depression following traumatic brain injury. *Arch Gen Psychiatry* 61:42-50, 2004.
20. Kamboh MI, Aston CE, Hamman RF: The relationship of APOE polymorphism and cholesterol levels in normoglycemic and diabetic subjects in a biethnic population from the San Luis Valley, Colorado. *Atherosclerosis* 112:145-159, 1995.
21. Maddocks D, Saling M: Neuropsychological deficits following concussion. *Brain Inj* 10:99-103, 1996.
22. Matser JT, Kessels AG, Jordan BD, Lezak MD, Troost J: Chronic traumatic brain injury in professional soccer players. *Neurology* 51:791-796, 1998.
23. Mirra SS, Heyman A, McKeel D, Sumi SM, Crain BJ, Brownlee LM, Vogel FS, Hughes JP, van Belle G, Berg L: The Consortium to Establish a Registry for Alzheimer's Disease (CERAD). Part II. Standardization of the neuropathologic assessment of Alzheimer's disease. *Neurology* 41:479-486, 1991.
24. Nathoo N, Chetty R, van Dellen JR, Connolly C, Naidoo R: Apolipoprotein E polymorphism and outcome after closed traumatic brain injury: Influence of ethnic and regional differences. *J Neurosurg* 98:302-306, 2003.
25. Nathoo N, Chetty R, van Dellen JR, Barnett GH: Genetic vulnerability following traumatic brain injury: The role of apolipoprotein E. *Mol Pathol* 56:132-136, 2003.
26. Omalu BI: Diagnosis of traumatic diffuse axonal injury. *Am J Forensic Med Pathol* 25:270, 2004.
27. Omalu BI, DeKosky ST, Minster RL, Kamboh MI, Hamilton RL, Wecht CH: Chronic traumatic encephalopathy in a National Football League player. *Neurosurgery* 57:128-134, 2005.
28. Pellman EJ: Background on the National Football League's research on concussion in professional football. *Neurosurgery* 53:797-798, 2003.
29. Pellman EJ, Lovell MR, Viano DC, Casson IR: Concussion in professional football: Recovery of NFL and high school athletes assessed by computerized neuropsychological testing—Part 12. *Neurosurgery* 58:263-274, 2006.
30. Pellman EJ, Lovell MR, Viano DC, Casson IR, Tucker AM: Concussion in professional football: Neuropsychological testing—Part 6. *Neurosurgery* 55:1290-1303, 2004.
31. Pellman EJ, Powell JW, Viano DC, Casson IR, Tucker AM, Feuer H, Lovell M, Waeckerle JF, Robertson DW: Concussion in professional football: Epidemiological features of game injuries and review of the literature—Part 3. *Neurosurgery* 54:81-94, 2004.
32. Pellman EJ, Viano DC, Casson IR, Arfken C, Feuer H: Concussion in professional football: Players returning to the same game—Part 7. *Neurosurgery* 56:79-90, 2005.

33. Pellman EJ, Viano DC, Casson IR, Arfken C, Powell J: Concussion in professional football: Injuries involving 7 or more days out—Part 5. *Neurosurgery* 55:1100–1119, 2004.
34. Pellman EJ, Viano DC, Casson IR, Tucker AM, Waeckerle JF, Powell JW, Feuer H: Concussion in professional football: Repeat injuries—Part 4. *Neurosurgery* 55:860–873, 2004.
35. Pellman EJ, Viano DC, Tucker AM, Casson IR; Committee on Mild Traumatic Brain Injury, National Football League: Concussion in professional football: Location and direction of helmet impacts—Part 2. *Neurosurgery* 53:1328–1340, 2003.
36. Pellman EJ, Viano DC, Tucker AM, Casson IR, Waeckerle JF: Concussion in professional football: Reconstruction of game impacts and injuries. *Neurosurgery* 53:799–812, 2003.
37. Pellman EJ, Viano DC, Withnall C, Shewchenko N, Bir CA, Halstead PD: Concussion in professional football: Helmet testing to assess impact performance—Part 11. *Neurosurgery* 58:78–96, 2006.
38. Porter MD: A 9-year controlled prospective neuropsychologic assessment of amateur boxing. *Clin J Sport Med* 13:339–352, 2003.
39. Roberts GW: Immunocytochemistry of neurofibrillary tangles in dementia pugilistica and Alzheimer's disease: Evidence for common genesis. *Lancet* 2:1456–1458, 1988.
40. Roberts GW, Allsop D, Bruton C: The occult aftermath of boxing. *J Neurol Neurosurg Psychiatry* 53:373–378, 1990.
41. Smith C, Graham DI, Murray LS, Nicoll JA:  $\tau$  immunohistochemistry in acute brain injury. *Neuropathol Appl Neurobiol* 29:496–502, 2003.
42. Smith DH, Chen XH, Nonaka M, Trojanowski JQ, Lee VM, Saatman KE, Leoni MJ, Xu BN, Wolf JA, Meaney DF: Accumulation of amyloid  $\beta$  and  $\tau$  and the formation of neurofilament inclusions following diffuse brain injury in the pig. *J Neuropathol Exp Neurol* 58:982–992, 1999.
43. Sortland O, Tysvaer AT: Brain damage in former association football players. An evaluation by cerebral computed tomography. *Neuroradiology* 31:44–48, 1989.
44. Teasdale GM, Nicoll JA, Murray G, Fiddes M: Association of apolipoprotein E polymorphism with outcome after head injury. *Lancet* 350:1069–1071, 1997.
45. Tokuda T, Ikeda S, Yanagisawa N, Ihara Y, Glenner GG: Re-examination of ex-boxers' brains using immunohistochemistry with antibodies to amyloid  $\beta$ -protein and  $\tau$  protein. *Acta Neuropathol (Berl)* 82:280–285, 1991.
46. Tysvaer AT, Lochen EA: Soccer injuries to the brain. A neuropsychologic study of former soccer players. *Am J Sports Med* 19:56–60, 1991.
47. Tysvaer AT, Sortland O, Storli OV, Lochen EA: Head and neck injuries among Norwegian soccer players: A neurological, electroencephalographic, radiologic and neuropsychological evaluation [in Norwegian]. *Tidsskr Nor Laegeforen* 112:1268–1271, 1992.
48. Tysvaer AT, Storli OV: Soccer injuries to the brain. A neurologic and electroencephalographic study of active football players. *Am J Sports Med* 17:573–578, 1989.
49. Tysvaer AT, Storli OV, Bachen NI: Soccer injuries to the brain. A neurologic and electroencephalographic study of former players. *Acta Neurol Scand* 80:151–156, 1989.
50. Viano DC, Casson IR, Pellman EJ, Bir CA, Zhang L, Sherman DC, Boitano MA: Concussion in professional football: Comparison with boxing head impacts—Part 10. *Neurosurgery* 57:1154–1172, 2005.
51. Viano DC, Casson IR, Pellman EJ, Zhang L, King AI, Yang KH: Concussion in professional football: Brain responses by finite element analysis—Part 9. *Neurosurgery* 57:891–916, 2005.
52. Viano DC, Pellman EJ: Concussion in professional football: Biomechanics of the striking player—Part 8. *Neurosurgery* 56:266–280, 2005.
53. Zhang L, Ravdin LD, Relkin N, Zimmerman RD, Jordan B, Lathan WE, Ulug AM: Increased diffusion in the brain of professional boxers: A preclinical sign of traumatic brain injury? *AJNR Am J Neuroradiol* 24:52–57, 2003.

## COMMENTS

This is an interesting study linking the chronic head trauma in professional football players with chronic traumatic encephalopathy. There is a temporal association of the symptoms with the patient's

football career. Also, it does not prove that head injury from playing football was the sole cause of this patient's disease; the association is intriguing and is important to report.

Kenneth Aldape  
Houston, Texas

The authors have had the opportunity to perform neuropathological studies on the brains of two National Football League (NFL) players with significant neuropathological differences in terms of the genotype, the presence (and absence) of amyloid plaques, and history. They concluded that a specific cohort of football players, such as those elected to the NFL Hall of Fame, should have autopsies and comprehensive postmortem neuropathological examinations regardless of pre-morbid conditions. The purpose would be to determine whether or not chronic neurodegenerative changes can be causally related to football participation.

From a scientific perspective, the goal certainly seems laudable. This case, however, exemplifies the difficulty in such a study. In their pre-mortem history, the authors state that, "within several years of his retirement from the NFL, his [present] wife reported that he became increasingly quiet, he was noted to be afraid and fearful with paranoid tendencies." They also report that he became extremely reclusive and distanced himself from all personal interactions with family and friends. Because the authors did not speak with his first wife, or obtain history from the players, trainers, and others with whom he associated in an intensely competitive environment for more than 8 years, the statement that abnormal behavior began "within several years of his retirement from the NFL" could certainly be challenged.

Indeed, after an automobile accident after his third year in the NFL, the authors state that medical records from a local psychiatric hospital indicated that he had the diagnosis of "a major depressive disorder, severe, without psychotic features." In 1990, 2 years before his retirement, he was suspended by the NFL for steroid abuse. The duration for which he used steroids is unrecorded or unknown.

In 1991, 1 year before his retirement, he attempted suicide by the ingestion of rat poison and cold medications, and, as the authors state, there were several other subsequent suicide attempts by ingestion of prescription drugs and antifreeze. After another suicide attempt in 2003 and the conviction for arson in 2005, he subsequently died from ingestion of ethylene glycol.

With such a multifactorial and incomplete history, I think it is extremely speculative to suggest that his psychosocial behavior and neuropathological findings are attributable to football-induced traumatic encephalopathy, especially because he demonstrated no residual evidence of a post concussion syndrome after his one documented cerebral concussion, after which he returned to full football participation for several years. Nevertheless, although more than daunting, to perform postmortem neuropathological examinations on all NFL Hall of Fame inductees would be of interest.

Joseph C. Maroon  
Pittsburgh, Pennsylvania

Onalu et al. report the second case of a relatively young, retired NFL player whose autopsy showed widespread changes, which they speculate may have been related to episodes of mild traumatic brain injury (MTBI) during his many years of contact sport participation. Pathological brain findings included widespread accumulation of  $\beta$ -positive neurofibrillary tangles and neuropil threads, a cavum septum pellucidum, but no hippocampal or cerebellar atrophy. This athlete's medical history, having participated in organized football for

14 years, had numerous episodes of behavioral abnormalities, along with a progressive major depressive disorder, multiple suicide attempts, and a completed suicide. However, there is no information concerning whether or not there were documented occurrences of clinical concussion related to football or if there were instances of MTBI at other stages of his life.

This report follows upon the authors' initial study of a similarly aged, football experienced, and psychologically disturbed retired NFL player whose autopsy findings showed both similar and contrasting features. Differences in this second case, although unclear if pertinent, were absence of amyloid plaques, an E3/E4 genotype, and diffuse topographic distribution of sparse to frequent neurofibrillary tangles and neuropil threads in not only the neocortex, but also the hippocampus, subcortical ganglia, and brainstem.

We now appreciate that, after sports concussion, a transient hypermetabolic state, axonal injury, a lower threshold for recurrence, and cumulative effects may occur (2, 6, 8). The old standard of a negative neurological examination and computed tomographic study to exclude central nervous system damage is no longer valid. Newer evaluations, focusing on white matter injury, hold promise to detect the presence of injury (1). Also, as McKeag has recently pointed out, there has been a previous tendency to overgeneralize in our approach to athletic MTBI and in studying its effects, as a wide range of variability in the type and expression of injury to the human brain is to be expected (7). Our previous study of former NFL players suggested that there was a correlation between the exposure to athletic MTBI and mild cognitive impairment seen in the later years after retirement (5).

Following on their initial case report, this autopsy study is of interest and further raises the question of the possibility of chronic or cumulative effects of multiple, subclinical concussions resulting in neurodegenerative changes in the form of accumulation of neuronal cytoskeleton and membrane proteins. Notwithstanding the absence of documentation of multiple clinical concussive episodes, this case nonetheless stimulates the discussion of whether or not, in a small number of players, such football exposure can cause a widespread neurodegenerative process with ultimate clinical manifestations.

It is uncertain whether or not these two case reports, unprecedented for such athletes, represent random findings or if there is a posttraumatic state which is akin to, but dissimilar enough not to satisfy all the classic neuropathological findings of, dementia pugilistica (3, 4). It remains an important, but unanswered question, which will have to be addressed by future necropsy and longitudinal population studies of athletes' exposure to known MTBI and subclinical concussions and their subsequent clinical and neurocognitive outcomes in the years after retirement.

**Julian E. Bailes**  
*Morgantown, West Virginia*

1. Bazarian JJ, Blyth B, Cimpello L: Bench to bedside: Evidence for brain injury after concussion—Looking beyond the computed tomography scan. *Acad Emerg Med* 13:199–214, 2006.
2. Collins MW, Lovell MR, Iverson GL, Cantu RC, Maroon JC, Field M: Cumulative effects of concussion in high school athletes. *Neurosurgery* 51:1175–1181, 2002.
3. Corsellis JA, Bruton CJ, Freeman-Browne D: The aftermath of boxing. *Psychol Med* 3:270–303, 1973.
4. Geddes JF, Vowles GH, Robinson SF, Sutcliffe JC: Neurofibrillary tangles, but not Alzheimer-type pathology in a young boxer. *Neuropathol Appl Neurobiol* 22:12–16, 1996.

5. Guskiewicz KM, Marshall SW, Bailes J, McCrea M, Cantu RC, Randolph C, Jordan BD: Association between recurrent concussion and late-life cognitive impairment in retired professional football players. *Neurosurgery* 57:719–726, 2005.
6. Hovda DA, Prins M, Becker DP, Lee S, Bergsneider M, Martin N: Neurobiology of concussion, in Bailes JE, Lovell MR, Maroon JC (eds): *Sports-related Concussion*. St Louis, Quality Medical Publishing, 1999, pp 12–51.
7. McKeag DB: Understanding sports-related concussion: Coming into focus but still fuzzy. *JAMA* 290:2604–2605, 2003.
8. Smith DH, Meaney DF: Axonal damage in traumatic brain injury. *Neuroscientist* 6:483–495, 2000.

This article adds to the increasing literature regarding cognitive deficits associated with low-grade repetitive head injury. Although, as a case report, no definitive statements can be made, it is important to have such cases presented and discussed. Although it is not possible to exclude a coincidental association of a psychiatric disorder in a professional NFL player, the degenerative pathology described would certainly be more in keeping with a traumatic etiology. Clearly, cases such as this provide an opportunity for more detailed studies looking at potential mechanisms underlying cognitive decline in chronic repetitive head injury, such as neuroinflammatory mechanisms. The genetic information relating to apolipoprotein E is of limited interest as a number of one (or two, when the previous report is included) is not informative.

**Colin Smith**  
**Neuropathologist**  
*Edinburgh, Scotland*

The authors present a case of autopsy-confirmed chronic traumatic encephalopathy in a retired professional football player with a history of neuropathological features. He had a 14-year history of involvement in organized football without multiple recorded concussions. After retirement, he was diagnosed with severe major depressive disorder and committed suicide 12 years after retirement. The contribution of anticoagulant rodenticide and ethylene glycol ingestion to his demise is unclear. The patient underwent an autopsy with restriction fragment length polymorphism analysis performed to determine apolipoprotein E genotype. His apolipoprotein E genotype was E3/E4, which would suggest, though not with certainty, a three- to ninefold increase in developing chronic posttraumatic neurodegeneration. Neurofibrillary tangles and neuropil threads were noted on evaluation of the cerebrum.

The authors compare and contrast this case with a previous case report. The relationship of the onset of his depressive disorder after his history of participation in football is purely temporal. This is a difficult relationship, given a potential history of antisocial behavior before his retirement. It becomes additionally more complex given a history of steroid use.

This report will hopefully bear subsequent studies, as the authors appropriately suggest, which will require long-term, longitudinal, multi-institutional and multi-disciplinary evaluation of genetic disposition, neuropsychiatric history, neuroradiological findings, clinical follow-up, and comprehensive postmortem neuropathological examinations.

**Min Park**  
**Andy Nguyen**  
**Michael L. Levy**  
*San Diego, California*